

The use of the LiteTouch Er:YAG laser in peri-implantitis treatment

Authors_Prof Tzi Kang Peng, Taiwan & Prof Georgi Tomov, Bulgaria

Introduction

With oral implantology experience its Renaissance, the growing incidence of peri-implantitis worldwide today is point of interest for both scientists and clinicians. Peri-implantitis is a disease of inflammatory nature which leads to the loss of the implant when left untreated.^{11,24} The aetiological factors of peri-implantitis are very similar to periodontitis.^{2,24} Different treatment modalities for the inflammatory soft tissue and bone lesions in peri-implants have been proposed—antibiotics, antiseptics, mechanical debridement, and surgical procedures have been suggested, depending on the grade of the clinical and radiographic manifestations.^{6,7,10,16,17}

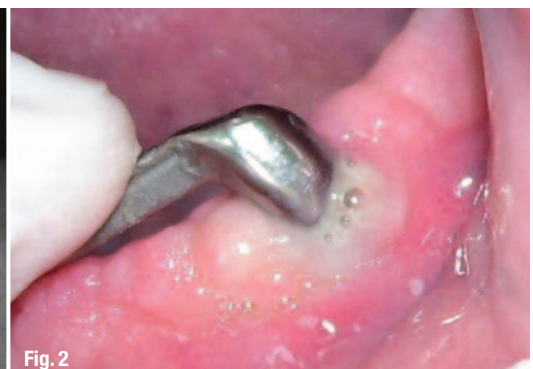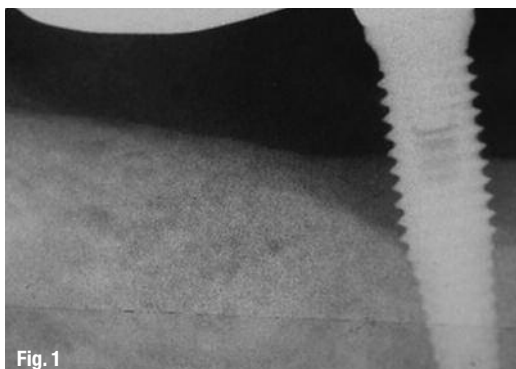
Treatment modalities such as scaling and root planing, used to treat roots with periodontitis, cannot be used in the same way on the threaded and retentive implant surfaces. The rough implant surface provides bacteria with shelter, unapproachable to conventional mechanical removal.²³ Conventional treatment procedures like closed peri-implant pocket debridement have shown limited success^{7,10} whereas the treatment of peri-implantitis using open-flap procedures has shown more promising results.¹⁷ Although the improved access to the implant surface

with open procedures can be seen as a fact, clinicians meet the same problems as encountered with open periodontal therapy. The decontamination of the retentive implant surface is much more complicated than the decontamination of a plane root surface.²³ The instruments used in periodontal treatment are too large to clean an implant surface from bacteria and any metal to metal contact during mechanical debridement has the potential to damage the implant surface.^{12,13} The common antiseptic therapy seems to be effective against bacterial biofilm in in vitro conditions.⁵ In addition, the local antibiotics used as an adjunct therapy to mechanical debridement has been advocated and shown to reduce bleeding on probing and probing pocket depth in patients with peri-implantitis,¹⁶ but there are no data supporting the effect of antibiotics on the decontamination of implant surfaces and more specifically the endotoxin elimination.^{10,16,18}

Currently, there are no clinical studies or case series documenting successful regenerative procedures in periimplant bony lesions after conventional treatment. Some case series demonstrated limited bone fill after GBR procedures.⁶ Another treatment modality that may offer an advantage over traditional mechanical treatment is the use of lasers.^{25,26}

Fig. 1_Periapical radiograph of a dental implant with bone loss of > 3 mm.

Fig. 2_ Implant site prior to measurement (implant supra-structure still in place). Pus discharge is evident.



THE NEW BONE GRAFT COMPOSITE OF THE 21TH CENTURY



HYPRO-OSS

is a patented, revolutionary, natural, atelopectidized and lyophilized bovine bone graft composite.

natural bovine bone composite with incorporated atelocollagen in each granule

30% collagen Type I free of telopeptide (atelocollagen) with native osteoinductive elements (TGF, BMPs, IGFs)

70% native osteoconductive bovine Hydroxyapatite components

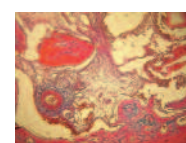
powerful haemostatic and bacteriostatic effects thanks to native atelocollagen components

excellent handling due to effective hydrophilic properties and optimal cell adhesion

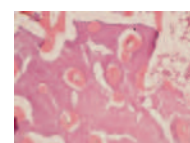natural crystalline structure and optimal porosity guarantees long term dimensional stability

user reported: no swelling or hematoma complications after sinus lifting or other implantation procedures

new bone formation within the shortest period of time ever



histology after 4 weeks



histology after 14 weeks

Studies have demonstrated that the treatment with an Er:YAG laser has a bactericidal effect.⁸ Er:YAG laser treatment can debride the implant surface effectively and safely without damaging.^{31,35} Much better clinical results have been reported for Er:YAG laser treatment compared with non-surgical mechanical debridement.^{15,27,31,35}

Aim

The aim of the (present study) intercontinental research led by Syneron was to assess the clinical outcomes of an open-flap procedure performed with conventional mechanical therapy (CMT) or laser-assisted surgical treatment (LAS) with the novel LiteTouch Er:YAG laser (Syneron Dental Lasers) in patients with implants and a diagnosis of peri-implantitis.

Materials and methods

The design was a single-masked, randomized six-month clinical intervention trial with two groups of patients diagnosed with peri-implantitis. The ethics committees of Cheng Hsin General Hospital, Taipei, Taiwan, and the Faculty of Dental Medicine, Plovdiv Medical University, Bulgaria, approved the study. Written consent was obtained from all enlisted patients. Patients were enrolled if they presented with at least one dental implant with bone loss of > 3 mm around the implant identified on intra-oral radiographs (Fig. 1), and with a PPD of > 5 mm with bleeding and/or pus discharge (Fig. 2) on probing. The study was conducted between September 2010 and August 2011 at the Cheng Hsin General Hospital and Plovdiv Medical University's Faculty of Dental Medicine. The following general criteria were used to exclude subjects from the study:

- subjects having taken medications likely to cause gingival hyperplasia within one month prior to baseline examination;
- subjects receiving regular periodontal maintenance treatment or having undergone any sub-gingival cleaning less than twelve months prior to baseline examination;
- subjects received peri-implantitis surgery of any type prior to baseline examination;
- subjects with clinically significant chronic illness (diabetes mellitus, compromised heart condition, rheumatism, joint replacement) requiring antibiotic prophylaxis;
- subjects having undergone systemic cancer therapy and/or radiation therapy at any time;
- subjects taking or having taken bisphosphonates;
- subjects having taken antimicrobials, steroids or non-steroidal anti-inflammatory drugs within one month prior to baseline examination;
- pregnant or lactating women;
- subjects engaged in excessive tobacco or alcohol intake or drug abuse.

Sixty-eight patients with a total number of 128 implants were included consecutively over a period of one year.

Clinical measurements

The measurement scale used in this study was constructed in order to obtain quantitative measurement data:

- PPD at four sites per implant (mm);
- presence/absence of BOP at the implant (four sites/implant), graded as follows:
- no bleeding, (1) point of bleeding, (2) line of blood and (3) drop of blood;
- bone loss (in mm on segment radiographs).

The PPD and BoP measurements were taken using a color-coded plastic periodontal probe (Kerr). All clinical measurements were obtained after removing the supras-structures. Intraoral standardized radiographs of sites of interest were obtained at baseline and at six months. Holders were used for standardization purposes. Radi-

bioimplon GmbH
Biotech Innovation Pioneers

Friedrich-List-Str. 27, 35398 Giessen, Germany
info@bioimplon.de
www.bioimplon.de

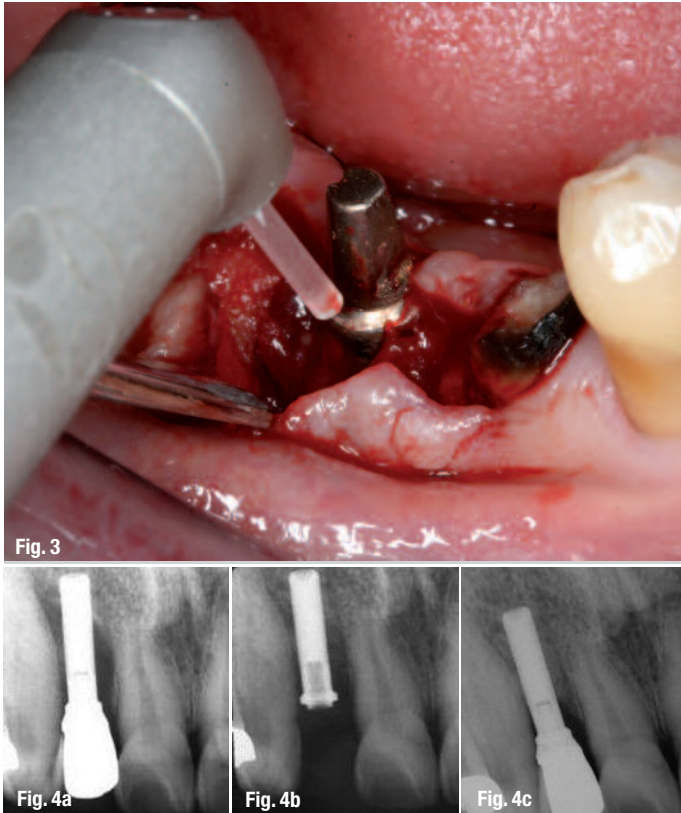

Fig. 3 Removal of plaque biofilm and granulation tissue using the LiteTouch Er:YAG laser with its 1.3 x 1.4 mm sapphire tip.

Fig. 4 The periapical radiograph revealed peri-implantitis with bone loss of > 5 mm (a). The abutment was removed and surgical treatment using the LiteTouch laser was performed. Bone grafting with a biomembrane followed the laser treatment (b). The periapical radiograph revealed bone regeneration after six months (c).

ographs were analyzed by two of the study investigators after previous calibration.

Hygiene phase (non-surgical phase)

Before treatment, the suprastructures were removed and the baseline measurements were taken. The goal of the initial phase was the reduction of as much tissue inflammation as possible. The patient moved on to the support phase once signs of improvement and reduction of inflammation had been observed. In case of persisting bleeding and pus discharge, a surgical procedure was planned. For this surgical phase, fifty-one of all sixty-eight patients with a total number of 100 implants were randomized with a lottery assignment.

Surgical phase

If there was no significant improvement after the non-surgical phase (in the second week), a surgical intervention was planned (surgical phase). Surgical intervention was indicated in cases in which the conditions around the implant had failed to improve after the initial phase, but plaque control was adequate, and there was a need to retain the contaminated implant. The supraconstruction of the implants was removed in order to gain access and to preserve as much soft tissue as possible to cover the area after surgery. Patients were randomly assigned to one of the two treatment regimens.

Conventional mechanical therapy (Group I)

Infiltration local anesthesia was used during treatment. The first incision was an internal gingivectomy, directed towards the bony ridge, which separates the peri-implant tissue from the mucosal flap. The flap was then raised to the level of the bony ridge, gaining access to the entire implant surface. The granulation tissue around the implant was carefully removed with sharp curettes and the implant surface was inspected for calculus deposits. The implant surface was then carefully cleaned using an ultrasonic device at low settings (PI tip, Piezon® ultrasonic unit, EMS). The PI tip was placed and used for approximately 60 seconds around the implant, ensuring coverage of the full circumference of the implant. Chemical debridement with a tetracycline solution was performed after ultrasound cleaning. In addition, bone augmentation was performed when required (21 patients; Bio-Oss, Geistlich Pharma; Dembone). During the study, all subjects received individualized oral hygiene instructions.

Laser-assisted surgical treatment (Group II)

Under local anesthesia, gingivectomy and the separation of the peri-implant tissue from the mucosa were performed. The flap was raised to the level of the bony ridge, gaining access to the entire implant surface. The granulation tissue around the implant was removed with the LiteTouch Er:YAG laser (Fig. 3). Tip of choice was 1,300 micron, noncontact mode (distance between end of the tip and target tissue = 1.5 mm). If calculus deposits were found, the implant surface was then carefully cleaned with laser. Decontamination with a non-contact, defocused Er:YAG laser was performed by systematically moving the laser tip along the surface. The area was rinsed with a sterile saline solution. Bone augmentation was performed when necessary (19 patients; Bio-Oss and Dembone with or without an absorbable biomembrane). The tips and settings used during treatment are given in Table 1.

Postoperative Instructions

The patients were prescribed clindamycin 150 mg x 50 tabs to avoid infection. They were also given ibuprofen 800 mg x 15 tabs for pain. Patients were instructed to rinse with chlorhexidine 0.2%, starting the next day, for two weeks three times a day, and were advised to maintain good oral hygiene.

Support phase

The goal of the support phase was to maintain long-term treatment results. Regular examination of the soft tissue, plaque control, radiographs and minor

Procedure	Hard tissue/ soft tissue	Contact/ non-contact	Laser energy (mJ)	Pulse frequency (Hz)	Tip diameter x length (mm)	Waterspray level
Releasing incision of the flap	Soft tissue	Contact	200	35	0.4 x 17	5–6
Granulation tissue ablation	Soft tissue	Non-contact	400	17	1.3 x 14	6
Bone remodelling	Hard tissue	Non-contact	300	25	1.3 x 19	8
Implant decontamination	Hard tissue	Non-contact	150	45	1.3 x 17	6
Decortication for GBR technique	Hard tissue	Non-contact	300	25	1.3 x 19	8

Table 1 Tips and settings used during laser treatment.

local treatments were performed, based upon the recall interval. If there was a recurrence of minor inflammation around an implant, the antibacterial periodontal treatment was repeated.

Statistical methods

A statistical software package (SPSS) was used for the statistical analysis. Statistical significance was defined by a p-value of < 0.05. A change in PPD was defined as the primary outcome measure. The secondary outcome measure was a change in bone height. The data was also analyzed using independent t-tests for continuous variables with a normal distribution (equal variance not assumed; PPD, changes in bone height) and using the Mann-Whitney U-test for non-parametric data (BoP, suppuration) and a chi-squared test.

Results

At baseline, a point of bleeding was found at 4.2% of all implant surfaces, a line of blood at 47.6% and a drop of blood at 56.9% of the sites. Statistical analysis failed to demonstrate baseline differences in BoP between different implant surfaces (p = 0.85). At six months, no evidence of bleeding was found in 81% of the implants in the LAS group and in 59% of the implants in the CMT group. The decrease in BoP was significant in both study groups (p < 0.001). Statistical analysis demonstrated differences in changes in BoP between the study groups (p < 0.001). The mean PPD reduction in the CMT and LAS groups was 0.8 mm (SD ± 0.5) and 1.7 mm (SD ± 1.3), respectively, with mean changes in bone height (loss) of -0.5 mm (SD ± 0.6) and -0.1 mm (SD ± 0.2), respectively (S) (Table 2). The proportional changes in bone height between baseline and six months, assessed from radiographs and defined at the implant level, are presented in Table 3. A positive treatment outcome, PPD reduction of > 4 mm and gain or no loss of bone were found in 59% of the CMT and 81% of the LAS groups, respectively (S). All subjects completed the study, and no implants were lost.

Discussion

In modern oral implantology, lasers have a considerable spectrum of clinical application. The literature data revealed that different laser wavelengths are used on peri-implant tissues: treatment of peri-implant mucositis, treatment of infrabony defects, removal of peri-implant hyperplastic overgrowth tissue, preparation of bone defects for GBR.^{3,4,22,28,29} Unlike mechanical decontamination methods, which cannot fully adapt to the irregularities on the surface of an implant, lasers can irradiate the whole surface, reaching areas that are too small to receive mechanical instrumentation. Recent in vivo studies have analyzed the outcome of peri-implantitis treatment using Er:YAG lasers^{1,21,27,31} and CO₂ laser.^{3,28,29} Many of these studies showed promising short-term results (less than six months), but report no long-term follow up. In the present study, differences in the reduction of BoP six months after treatment were found between LAS and CMT groups. While oral hygiene had improved greatly and no plaque was found at the treated implants, a large proportion of the implants in the CMT group continued to exhibit BoP at the six-month post-treatment assessments. In the present study, BoP was graded to distinguish the severity of inflammation and approximately 14% of the implants in the LAS and 41% in the CMT groups presented with bleeding, which was consistent with other data.³⁰ The reasonable explanation for these results is the quality of decontamination of the implant surface provided by the treatment approaches evaluated.

Contaminants such as bacteria and their by-products, calculus, and granulations should

Table 2 Proportional changes in PPD between baseline and six months, defined at the implant level based on the mean value of changes at four sites/implant.

PPD changes	CMT (%)	LAS (%)
Decrease (mm)		
> 4	1.2	37.4
3.1–4.0	7.9	35.0
2.1–3.0	14.0	7.9
1.1–2.0	35.4	12.1
0.1–1.0	1.7	4.2
Unchanged (mm)		
0.0	29.2	1.4
Increase (mm)		
0.1–1.0	7.9	0.0
1.1–2.0	1.2	0.0
2.1–3.0	1.0	0.0
3.1–4.0	0.0	0.0

Radiographic changes in bone height	LAS (%)	CMT (%)
Decrease (loss in mm)		
1.1–2.0	12.2	35.4
0.1–1.0	37.1	39.5
Unchanged (mm)		
0.0	29.3	4.2
Increase (gain in mm)		
0.1–1.0	17.4	12.5
1.1–2.0	4.9	2.1
2.1–3.0	7.1	6.3

Table 3 Proportional changes in bone height between baseline and six months, defined at the implant level based on the mean value of changes in mesial and distal bone height.

be removed without modifying the implant surface and with respect to surrounding soft tissues. Numerous methods for the decontamination of implant surfaces have been suggested, either alone or in various combinations, as part of the surgical treatment of peri-implantitis. The literature data revealed that methods as cleaning with metal curettes and inappropriate ultrasonic tips or irradiation with Nd:YAG laser can damage the implant surface and could compromise the residual implant stability.^{9,20} Air-powder abrasive units are often recommended for the surgical treatment of peri-implantitis. A recent study aimed at evaluating the influence of different air-abrasive powders on cell viability at biologically contaminated titanium dental implant surfaces revealed that no surface treatments led to mitochondrial cell activity values comparable to the sterile control group.³³ Citric acid application and sandblasting have also been recommended.¹⁸ However, implant decontamination using sandblasting units have been associated with risks such as soft tissues damage and emphysema.³⁴

Er:YAG lasers are seen as the most promising new technical modalities of treating failing dental implants, since their performance of tissue ablation is accompanied by a high bactericidal and detoxification effect.^{26,32} When considering the use of Er:YAG lasers in the treatment of peri-implantitis, there are some crucial points with clinical importance. Power settings are variable, and the clinician must also choose a setting that will effectively disinfect the implant while not damaging the surface. A narrow range of power settings (100 mJ/pulse) was described in the literature.^{21,27,30,31,32} Only one study used a higher power setting of 120 mJ/pulse.¹ The frequency was set at 10 Hz for each of the mentioned studies, however, neither the distance from which the laser was applied, nor the time of application to each implant was stated. In the present study, the settings used for implant surface decontamination are 150 mJ/45 Hz, at non-contact mode and constant movement. Another important point is the interaction between laser light and metal surfaces. This interaction is mainly determined by the degree of absorption and reflection. With a reflectance capacity of about 71%,¹⁹ titanium implant surfaces do not absorb irradiation. Consequently, there is no increase in temperature which could damage the implant surface. Several investigations have reported on the promising ability of the Er:YAG lasers in implant surface debridement without producing thermal side-effects on implant surface

and adjacent tissues.^{14,35} Treatment of peri-implantitis using Er:YAG laser therapy has been investigated before and appears to result in a more effective reduction in bleeding around implants than surgical debridement with hand instruments and sub-gingival application of chlorhexidine.^{1,27,30,31} Irradiation with this specific wavelength seems to have a bactericidal effect on periodontopathic bacteria and remove bacterial biofilm. However, in order to treat the implants with the laser device in the present study, the suprastructures were removed, allowing the access to the implant surfaces to improve. Thus, the results of the present study are limited to implants where the suprastructures can be removed during treatment.

Conclusion

Among lasers used in the field of dentistry, the Er:YAG laser seems to possess the characteristics most suitable for peri-implantitis treatment because of its ability to ablate both soft and hard tissue, as well as bacterial biofilm and calculus, without causing thermal damage to the adjacent tissues and implant surfaces. The decontamination effects of Er:YAG laser are also beneficial regarding peri-implantitis pathogenesis. In the present study, the use of the LiteTouch Er:YAG laser has been proposed for the treatment of peri-implantitis and the results indicate that the laser-assisted surgical therapy may lead to significant clinical improvements such as BoP and PPD reduction as well as a gain in clinical attachment. From a clinical point of view, these results advocate the Er:YAG laser as an alternative treatment modality to conventional mechanical therapy.

With the collaboration of Dr Ke, Dr Yu, Dr Lu, Taiwan; Dr Kenny Chiu, Hong Kong; Drs Kanbayashi, Takahashi, Ikeda & Kamiya, Japan.

Editorial note: A list of references is available from the publisher.

_contact	laser
<p>Prof Tzi Kang Peng DDS, MS, PhD, FICD Professor and Chair of the Department of Dentistry Cheng Hsin General Hospital Taipei, Taiwan</p>	
<p>Assoc Prof Georgi Tomov DDS, MS, PhD Associate Professor and Chair of the Department of Oral Pathology, Faculty of Dental Medicine Medical University of Plovdiv, Bulgaria</p>	